ISSN : 2347 - 2243

Indo - American Journal of Life Sciences and Biotechnology

www.iajlb.com
Email : editor@iajlb.com or iajlb.editor@gamil.com

ISSN 2347-2243
www.iajlb.com
Indo-Am. J. of LifeSc & Bt.,2024- Vol.21, Issue.2June,2024

Indo-American Journal of Life Sciences and Biotechnology

A case report of infertility caused by a uterine fibroid that was successfully managed with constitutional homoeopathic medications

Keshav Narayan Bodhale

Abstract
Primary and secondary infertility are two main categories into which infertility can be divided. Primary infertility is the inability to procreate in a couple that has never had a child, while secondary infertility is the inability to conceive after a previous live birth. Infertility may be caused by specific pathology in males (20-30%), females (30-50%), and the inexplicable (25-30%). Uterine fibroid (UF) is observed in 5-30% of female infertile patients. A case report of a 32-year-old married female who has been experiencing secondary infertility with UF for four years is presented below. After a two-year period of normal conjugal life, the couple had consulted with a gynecologist, who diagnosed her with UF (>3cm). However, they were unable to conceive spontaneously. Despite two years of conventional medical treatment, she did not achieve a successful outcome. Consequently, surgery was recommended. She was treated with constitutional homoeopathic medications (Sepia and Natrum muriaticum) for a period of six months at this juncture. She conceived spontaneously and delivered a healthy female child at full term without any complications. This case illustrates the beneficial impact of constitutional homoeopathic treatment on secondary subfertility associated with UF.

Keywords: Secondary infertility, uterine fibroids, homoeopathy, sepia, natrum muriaticum

Introduction

The uterine fibroids (UF) or leiomyoma are the most prevalent benign gynecological tumors in women, particularly during their reproductive years, afflicting 20–50% of these women [1-3]. It is anticipated that 70-80% of women will develop a fibroid during their lifetime [4]. The incidence of UF in infertile women without any apparent cause of infertility is estimated to be 1- 2.4%, and it is present in 5-30% of infertile patients. Fibroids are reported in 0.1% to 10.7% of all pregnancies. The true prevalence of UFs is significantly higher, as many fibroids are asymptomatic, despite the fact that they afflict approximately 35-77% of reproductive-age women [5-6]. Pelvic pain, menorrhagia, impingement, infertility, and associated complications are among the diverse clinical consequences of UF. Spontaneous abortion, pelvic outlet obstruction, fetal malpresentation, cesarean section, premature labor, and postpartum hemorrhage are complications that occur in approximately 10-40% of pregnancies. If the fibroids exceed 3 cm in size, the likelihood of complications during pregnancy increases. Death is almost never associated with the presence of myomas; however, they may result in morbidity and impact the quality of life. The mechanism by which fibroids may cause infertility is subject to significant variation, as is their size, location, and number. The distribution of UF is broadly classified as intramural or interstitial (75%), submucous (15%), and subserous (10%). It is generally recognized that anatomical location is a significant factor, with submucus, intramural, and subserous fibroids being implicated in the development of infertility in descending order. In a retrospective comparative study of patients with UF and those without UF, it was determined that the rates of pregnancy and implantation were significantly lower in patients with intramural and submucous fibroids, even in the absence of uterine cavity deformation (PR: 16.4 and 10%, respectively, compared to 30% in the control group). However, the proportion of subserous fibroids did not affect the results. Submucosal and intramural fibroids exhibited significantly higher rates of spontaneous abortion and lower rates of live births. Meta-analyses conducted in numerous studies have demonstrated that the Implantation Rate, Clinical Pregnancy Rate, Low Birth Rate, and Miscarriage Rate are substantially diminished by the presence of noncavity-distorting intramural fibroids, as compared to women who do not have fibroids [7-10].

PSPM MAHILA HOMEOPATHIC MEDICAL COLLEGE
Solapur

The management of UF is controversial, and the diagnosis is confirmed by pelvic ultrasound. Medical therapies, surgery, and newer options, including MRI-guided focused ultrasound (MRgFUS) and uterine artery embolization (UAE), are all available treatments for UFs. The appropriate treatment for each patient will be contingent upon their age, desire to preserve their uterus, and future fertility.

Medical therapies are considered as the first-line treatment but their long term uses develop adverse effects. Surgery/myomectomy is still the better choice for women who desire to have a child but it may cause the risk of significant morbidity like infection, postoperative adhesion formation, infertility and its permanently removal is difficult. The fertility improvement outcome is still questionable after myomectomy in women. UAE though hasan advantage over myomectomy and hysterectomy for symptomatic uterine fibroids but is associated with a higher rate of complications. Designing individualized management plans will ensure optimal outcomes and maximal patient satisfaction [10-12].

Literature review in Homoeopathy revealed studies [13-14] and case reports [15-16] in which uterine fibroids had been treated successfully with homoeopathic medicine. It also had been shown in the review article of 'Homeopathic treatment of infertility: A medical and bioethical perspective', the author has observed the homoeopathicapproach and the bioethical implications to infertility andproposed that monitoring the effects of homoeopathicremedies on infertile women may be an effective method toassess the efficacy of this form of alternative medicine [17] Here, I presented a case of secondary infertility in a femalewith having UF who was long been treated with modernmedical therapies but no spontaneous conception had beenachieved and finally she was advised for surgery. Foravoiding the surgery she attended to Out Patient Department of Dr. Anjali Chatterjee Regional Research Institute for Homoeopathy [(DACRRI)-H], Kolkata for Homoeopathictreatment.

History of present illness

There was history of spontaneous first pregnancy and normally delivered a male child at local hospital without anycomplications. Her first child is eight years old. After four years of her first child, couple tried for last 2.5 years for second issue but failed to conceive. There after she consulted and took treatment by Gynecologist for conception and that time incidentally she was diagnosed with UF which was revealed by Pelvic ultrasound (report was misplaced). She was treated with medical therapies by Gynecologist for 1.5 years but no positive results were found. On dated 12-07-18, Pelvic ultrasound was done which revealed a large UF, measuring 3.4 x 2.4 x 1.9 centimeters (Fig.1) in the anterior wall of the fundus of uterus and then Gynecologist advised her for surgical removal of UF for spontaneous pregnancy. The patient did not agree for surgery and finally she landed up at DACRRI for homoeopathic treatment for UF with hope of pregnancy for second time.

Her menstrual cycle was early (Menstrual cycle -23-25 day) with moderate flow lasting for 5–6 days or more associated with pelvic pain. She has dark complexion and normal BMI (height - 152; weight- 58 kgs; BMI 27.055). There was a history of Leucorrhoea < daytime.

There was a history of chicken pox at 12 years of age. She has been suffering from rhinitis and dust allergy last two years. There was a history of chronic obstructive pulmonarydisease in her father and hypertension in her mother. Another family history was not reported.

Homoeopathic generalities

For totality of symptoms the general symptoms (mental & physical generals) were considered along with disease symptoms.

Mental generals

Sad, depressed with melancholic appearance. Always thinking about her health. Anxious about surgery for UF andher secondary fertility. She prefers being alone and a quiet environment. She is mild, reserve, introvert and does not express herself to others.

Physical generals

Her menstrual cycle was regular (28-30 days) but last 6 months cycle become early (22-24 days), with moderate flow, dark clotted, associated with lower abdominal pain < during menses; leucorrhoea – thick or thin mucus < during day time. She also had decreased appetite with moderate thirst. She has the tendency of constipation with passing dry,hard, stool. She was thermally ambithermic; There was desire meat++, cold food+++ and spicy food++ & aversion to bread+; profuse sweat in all over the body, offensive; sleeplessness for last few months due to anxiety for her diseases. Headache with band like sensation < noise and mental exertion.

A detailed case taking was done to construct the totality, as per principles of Homoeopathy.[18] After evaluation and analysis of symptom totality the following characteristics symptoms were considered for repertorisation. Using the Kent Repertory, by Hompath Classic M.D Software, Ver.

1.0. repertorial analysis was done [19-20] [Table 1].

The following characteristic symptoms were considered for repertorisation:

- Sad, depressed with melancholic appearance.
- Always thinking about her health and disease
- Fear and anxious about disease <thinking complaints.
- She prefers being alone and a quiet environment
- Forgetful, cannot remind things where kept
- Infertility
- Menses regular, mostly early
- Menses – more clotted, offensive
- Pain in lower abdomen, more during menses
- Leucorrhoea – thin or thick mucus < day time
- Desire for meat+++ spicy foods++
- Desire for cold food+++
- Aversion to bread^{++}.
- Profuse offensive perspiration on axial and inguinal regions /flexor parts.

Table 1: Repertorisation software chart

Normal
Repertorisation

	Sep	Sulph	Nat-m	Calc	Lach	Lyc	Nux-v	Graph	Kali-c	Phos	Puls	Sil	Plat	Rhus-t	Nit-ac
Totality	30	25	24	24	23	22	21	21	20	20	20	20	19	17	17
Symptoms Covered	14	12	11	10	11	9	12	8	11	10	9	9	10	9	8
[KT] [Mind]Sadness,mental depression:	3	3	3	3	3	3	2	3	2	2	3	2	3	3	3
[KT] [Mind]Anxiety:Health,about:	2	1		2	1		1		1	2	1	1			3
[KT] [Mind]Company:Aversion to:	2	2	3	1	2	2	3	1	1	1	2		2	2	
[KT] [Stomach]Desires:Sweets:	2	3	1	2		3	1		2					2	
[KT] [Stomach]Desires:Bitter food:			2												
[KT] [Stomach]Aversion:Bread:	2	1	3		1	2	2		2	2	2			1	2
[KT] [Genitalia female]Menses:Early,too:															
[KT] [Genitalia female]Menses:Clotted:	1	2	2	3	3	2	1		1		3		3	3	1
[KT] [Genitalia female]Menses:Painful,dysmenorrhoea:	2	2	1	2	2	2	2	2	3	2	2	1	2	2	1
[KT] [Genitalia female]Tumours:Uterus:Fibroid:				3	2	2	1		2	3		2	1		1
[KT] [Genitalia female]Leucorrhoea:Menses:Before:	3	2	2	3	2			3		2	2	2	1		
[KT] [Genitalia female]Leucorrhoea:Daytime only:	1												1		
[KT] [Perspiration]Odour:Offensive:	3	3			2	3	3	3	1	2	3	3		2	3
[KT] [Head]Pain,headache in general:Closing eyes:Amel:	2	2	1	2			1					3	1	1	
[KT] [Rectum]Constipation:Menses:During:	3	1	3				1	3	3	1		3	3		
[KT] [Rectum]Constipation:Stool remains long time in the rectum with n	1				2			3							
[KT] [Stool]Hard:	3	3	3	3	3	3	3	3	2	3	2	3	2	1	3

Symptoms 1 to 17 Total Symptoms : 17 Remedies 1 to 15 Total Remedies : 297

Clinical findings and diagnostic assessment

On previous clinical findings and Pelvic ultrasound revealed it was found to be a case of a large UF with secondary fertility. She had taken treatment from Gynaecologist for spontaneous conception from 2016 to 2018 off and on. It was found that there was no any other significant pathological cause or reproductive factors (male factors, tubal, ovarian and hormonal factors) for failure to conceive except uterine fibroid. Based on detailed workup byGynaecologists and clinical evaluation, this was found to be a case of Subfertility due to large uterine fibroid.

Therapeutic intervention, follow-up and outcome

Homoeopathic medicines were procured from Hahnemann Publishing Company Pvt. Ltd. (Good ManufacturingPractice certified ISO 9001:2008 unit) and dispensed from DACRRI (H) dispensary. The homoeopathic Similimum Sepia was prescribed on the basis of symptom similarity, individualisation, and miasmatic analysis with the holistic concept of Homoeopathy. Treatment was started withconstitutional homoeopathic medicine *Sepia* with increasing potencies (200C, 1M, 10M) and completed with itscomplementary medicine Natrum muriaticum [21-24] Sepia initiated the improvement and Natrum muriaticumcompleted the cure, i.e., natural conception has been occurred in patient. Pelvic Ultrasound [Fig.3] revealed a gestational sac with significant regression of UF in size, measuring 10 x 12 x 8 mm. Over a period of five months of treatment with individualized constitutional homoeopathic medicine Sepia and Natrum muriaticum have given successful result in patient with secondary infertility and UF. Finally without any complications the patient delivered normally a mature healthy female baby [Figure.4].

The final outcome and possible causal attribution of the changes in this case were assessed using the 'Modified Naranjo Criteria' as proposed by the HPUS Clinical data Working Group [25] (December 2015) [Table 3]. The total score of outcome as per the Modified Naranjo Criteria was 09, which was close to the maximum score 13. This explicitly shows the positive causal attribution of the individualized homoeopathic treatment towards this case of uterine fibroid with secondary infertility.

The evidences of UF and infertility have been submitted as images (Before, during and after treatment) as follows:

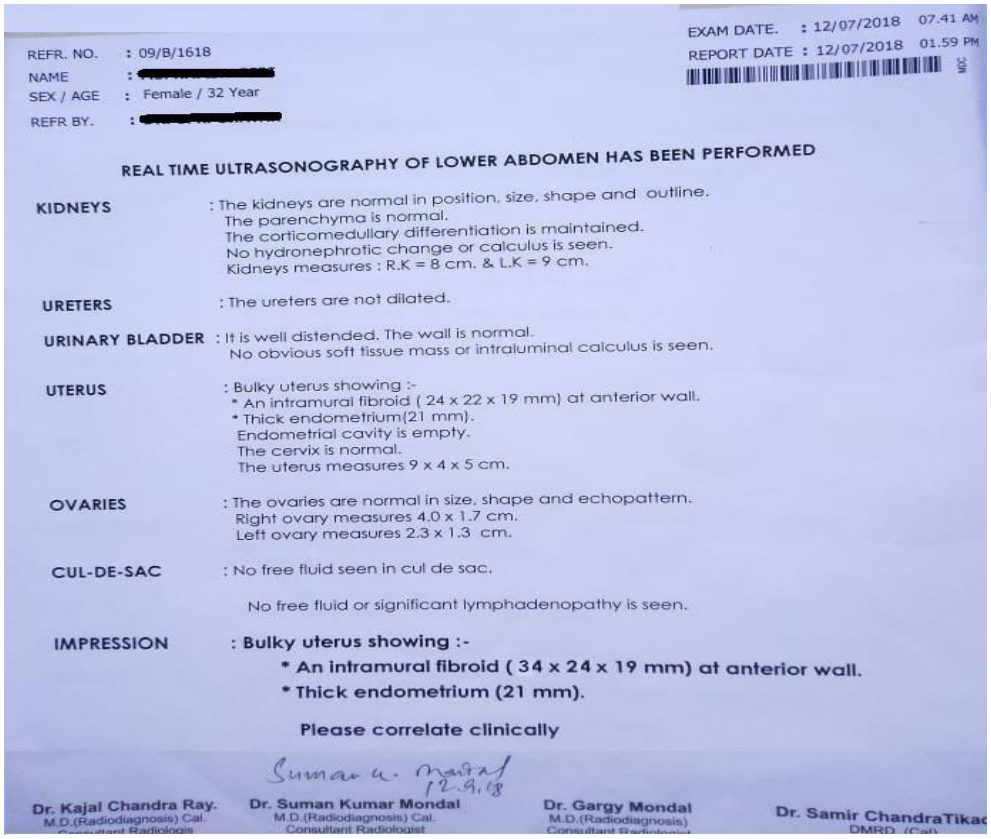

EXAM DATE. : 12/07/2018 07.41 AM
REPORT DATE : 12/07/2018 01.59 PM

REFR. NO. : 09/B/1618
NAME : [redacted]
SEX / AGE : Female / 32 Year
REFR BY. : [redacted]

REAL TIME ULTRASONOGRAPHY OF LOWER ABDOMEN HAS BEEN PERFORMED

KIDNEYS : The kidneys are normal in position, size, shape and outline.
The parenchyma is normal.
The corticomedullary differentiation is maintained.
No hydronephrotic change or calculus is seen.
Kidneys measures : R.K = 8 cm. & L.K = 9 cm.

URETERS : The ureters are not dilated.

URINARY BLADDER : It is well distended. The wall is normal.
No obvious soft tissue mass or intraluminal calculus is seen.

UTERUS : Bulky uterus showing :-
* An intramural fibroid (24 x 22 x 19 mm) at anterior wall.
* Thick endometrium(21 mm).
Endometrial cavity is empty.
The cervix is normal.
The uterus measures 9 x 4 x 5 cm.

OVARIES : The ovaries are normal in size, shape and echopattern.
Right ovary measures 4.0 x 1.7 cm.
Left ovary measures 2.3 x 1.3 cm.

CUL-DE-SAC : No free fluid seen in cul de sac.

No free fluid or significant lymphadenopathy is seen.

IMPRESSION : **Bulky uterus showing :-**
*** An intramural fibroid (34 x 24 x 19 mm) at anterior wall.**
*** Thick endometrium (21 mm).**

Please correlate clinically

Suman K. Mondal 12.9.18

Dr. Kajal Chandra Ray. M.D.(Radiodiagnosis) Cal. Consultant Radiologis
Dr. Suman Kumar Mondal M.D.(Radiodiagnosis) Cal. Consultant Radiologist
Dr. Gargy Mondal M.D.(Radiodiagnosis) Consultant Radiologist
Dr. Samir ChandraTikad DMRD (Cal)

Fig 1: Pelvic USG report before treatment.

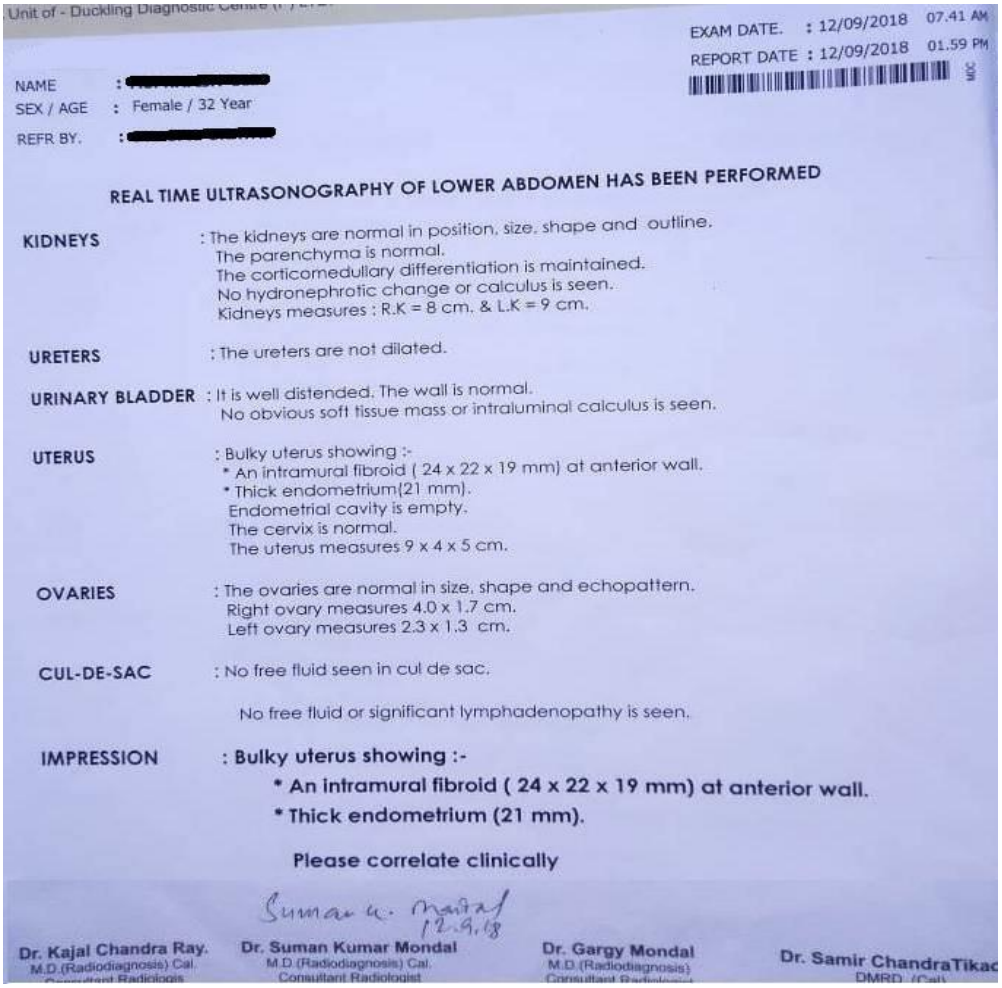

Unit of - Duckling Diagnostic Centre

EXAM DATE. : 12/09/2018 07.41 AM
REPORT DATE : 12/09/2018 01.59 PM

NAME : [redacted]
SEX / AGE : Female / 32 Year
REFR BY. : [redacted]

REAL TIME ULTRASONOGRAPHY OF LOWER ABDOMEN HAS BEEN PERFORMED

KIDNEYS : The kidneys are normal in position, size, shape and outline.
The parenchyma is normal.
The corticomedullary differentiation is maintained.
No hydronephrotic change or calculus is seen.
Kidneys measures : R.K = 8 cm. & L.K = 9 cm.

URETERS : The ureters are not dilated.

URINARY BLADDER : It is well distended. The wall is normal.
No obvious soft tissue mass or intraluminal calculus is seen.

UTERUS : Bulky uterus showing :-
* An intramural fibroid (24 x 22 x 19 mm) at anterior wall.
* Thick endometrium(21 mm).
Endometrial cavity is empty.
The cervix is normal.
The uterus measures 9 x 4 x 5 cm.

OVARIES : The ovaries are normal in size, shape and echopattern.
Right ovary measures 4.0 x 1.7 cm.
Left ovary measures 2.3 x 1.3 cm.

CUL-DE-SAC : No free fluid seen in cul de sac.

No free fluid or significant lymphadenopathy is seen.

IMPRESSION : **Bulky uterus showing :-**
*** An intramural fibroid (24 x 22 x 19 mm) at anterior wall.**
*** Thick endometrium (21 mm).**

Please correlate clinically

Suman K. Mondal 12.9.18

Dr. Kajal Chandra Ray. M.D.(Radiodiagnosis) Cal.
Dr. Suman Kumar Mondal M.D.(Radiodiagnosis) Cal. Consultant Radiologist
Dr. Gargy Mondal M.D.(Radiodiagnosis)
Dr. Samir ChandraTikad DMRD (Cal)

Fig 2: Pelvic USG report during treatment (reduction of size of UF)

REFR. NO. : 01/B/2274
NAME : [redacted]
SEX / AGE : Female / 32 Year
REFR BY. : [redacted]

BILL DATE : 18/01/2019 07.13 AM
LAB RECEIPT DATE : 18/01/2019 07.13 AM
REPORT DATE : 18/01/2019 11.46 AM

REAL TIME ULTRASONOGRAPHY OF LOWER ABDOMEN HAS BEEN PERFORMED

POST VOID STUDY : Empty urinary bladder.

UTERUS : Retroverted, bulky gravid uterus showing single wellformed intrauterine gestational sac with MSD of 1.43 cm. corresponding to 6 weeks 3 days (± 5 days) maturity . Cardiac activities noted . Retrochorionic space is normal. A small (10 x 11 mm) intramural fibroid at anterior wall of body of uterus. Internal OS is closed. The cervix is normal, measures 3 cm.

OVARIES : The ovaries are normal in size, shape and echopattern. Right ovary measures 3.0 x 0.9 cm. Left ovary measures 2.9 x 2.6 cm.

CUL-DE-SAC : No free fluid seen in cul de sac.

No free fluid or significant lymphadenopathy is seen.

IMPRESSION : 1) Retroverted, bulky gravid uterus showing single wellformed intrauterine gestational sac with MSD of 1.43 cm. corresponding to 6 weeks 3 days (± 5 days) maturity . Cardiac activities noted .

- Suggested follow-up study

2) A small (10 x 11 mm) intramural fibroid at anterior wall of body of uterus.

* I, the undersigned declare that while conducting the ultrasound of Ms. Hafiza Bibi
* I have neither detected nor disclosed the sex of her foetus to any body in any manner.

Suman K. Mondal 18.1.19

Dr. Kajal Chandra Ray. M.D.(Radiodiagnosis) Cal. Consultant Radiologis Regd. No. 52369 (WBMC)
Dr. Suman Kumar Mondal M.D.(Radiodiagnosis) Cal. Consultant Radiologist Regd. No. 55280 (WBMC)
Dr. Gargy Mondal M.D.(Radiodiagnosis) Consultant Radiologist Regd. No. 59250 (WBMC)
Dr. Samir ChandraTikade DMRD. (Cal) Consultant Radiologist Regd. No. 39752 (WBMC)

Fig 3: Pelvic USG report during treatment (Spontaneous conception with reduced size of UF &)

Patient Name : [redacted]
Patient ID : 2135 /19-20
Ref By : [redacted]

Sex : Female Age : 32 y
Date of Scan : 19/08/2019

ULTRASOUND REPORT FOR STANDARD OBSTETRICS

Average Fetal Age	34 w 06 d *	LMP	08/12/2018
Estimated Fetal Weight	2372 g + 16%	Age by LMP	36 w 02 d

Reason for study : Follow up
Foetal heart rate is : 148 / BPM

Foetal parameters are :
Number of foetus : Single.
Presentation : Cephalic.
Fetal body and limb movements : Adequate
Foetal neck : Free.

Real-time ultrasonography of foetus reveals:
Estimated Gestation Age by Fetal Parameters

BPD	: 86.6 mm	GA	35 W	0 D
HC	: 315.1 mm	GA	35 W	3 D
AC	: 297.5 mm	GA	33 W	5 D
FL	: 69.0 mm	GA	35 W	3 D

Maternal parameters :
Placenta :
Number : Single.
Location : Right lateral , high up .
Grade : " II+ "
Subplacental collection : Nil

Cervix :
Length (L/W) : L- 31.0 mm / W- 27.0 mm
Internal os and canal : Closed.

Liquor amnii :
Volume : Adequate
Pocket size (average) : 35.8 mm

** One myoma (33.4mm / 20.6mm) seen at anterior uterine wall.

IMPRESSION :
Single live intrauterine pregnancy.
Adequate amount of ammiotic fluid is present.

DR. RANJAN SUKLA GHOSH
MBBS, DMRD (Cal)
Senior Consultant, invasive Radiology

Fig 4: Pelvic USG report during pregnancy with foetal profile. (After treatment)

Table 2: Timeline including follow-up with intervention

Date of 1st visit and follow ups	Indications/Symptoms	Prescribed medicine with potency & doses
20-07-2018	Baseline presentation Date of Last Menstrual period was- 15/07/2018	Sepia 200C/3 doses (D) once daily (OD) for 3 days
16-08-2018	LMP- 08/08/18; Menses –early, (cycle-24 days), but flow- dark, clotted, offensive; Pain in lower abdomen, more during menses- persist; Leucorrhoea – same; stool- hard & other symptoms –same	Placebo 30 is given
12-09-2018	LMP- 02/09/18; Menses- early but regular (cycle-25 days), Pain during menses- less , flow better but dark & clotted, leucorrhoea- less, constipation- more hard stool causes anal pain ; disturbed sleep; anxiety –more for failure to conception, Headache-persist.	Sepia 1M/2D/OD for 2 days
10-10-2018	LMP- 30/09/18; Menses- regular (cycle-28 days) but pain in lower abdomen during menses- less, No leucorrhoea, more anxious & more depressed about issue, Repeated the medicine for further improvement.	Sepia 1M/2D/OD for 2 days
12-11-2018	LMP- 30/10/18; Menstruation –reg[redacted]le-30 days) Stand still condition. For further improvement the complementary medicine was prescribed.	Natrum Muriaticum 1M /3D/OD for 3 days
13-12-2018	LMP- 30/11/18 Regular cycle , Flow-moderate, clotted –less , no pain during - less; No Leucorrhoea, Headache- less, constipation- better , Anxiousness & depression - persists.	Natrum Muriaticum 1M /3D/OD for 3 days
10-01-2019	LMP- 01/12/18; No menses appear. Amenorrhea since one month. Advise for Urine Pregnancy Test on 15/01/18.	No medicine
16-01-2019	Reported pregnancy test – positive. She feels happy. Advise for rest and avoid physical exertion. Advised for Pelvic ultrasound with fetal profile to find out gestational sac	
24-01-19	Pelvic ultrasound was done on 18-01-18 which showed pregnancy with intrauterine gestational sac (Fig.3). A single intrauterine pregnancy of 6 weeks 3 days maturity with regression of UF in size. She became happy for spontaneous conception.	
20-12-2019		

Table 3: Assessment by Modified Naranjo Criteria score

S. no.	Item	Yes	No	Not sure or N/A
1	Was there an improvement in the main symptom or condition for which the homoeopathic medicine was prescribed?	+2	-1	0
2	Did the clinical improvement occur within a plausible time frame relative to the drug intake?	+1	-2	0
3	Was there an initial aggravation of symptom? (need to define in glossary)	+1	0	0
4	Did the effect encompass more than the main symptom or condition, i.e., were other symptoms ultimately improved or changed?	+1	0	0
5	Did overall wellbeing improve? (suggest using validated scale)	+1	0	0
6 (A)	Direction of cure: did some symptoms improve in the opposite order of the development of symptoms of the disease?	+1	0	0
6 (B)	Direction of cure: did at least two of the following aspects apply to the order of improvement of symptoms -from organs of more importance to those of less importance - from deeper to more superficial aspects of the individual - from the top downwards .	+1	0	0
7	Did öld symptoms"(defined as non-seasonal and non-cyclical that were previously thought to have resolved) reappear temporarily during the course of improvement?	+1	0	0
8	Are there alternate causes (other than the medicine) that-with a high probability- could have	-3	+1	0

	caused the improvement? (consider known course of disease, other forms of treatment and other clinically relevant intervention			
9	Was the health improvement confirmed by any objective evidence? (e.g. lab test, clinical observation, etc.)	+2	0	0
10	Did repeat dosing, if conducted, create similar clinical improvement?	+1	0	0
	Total score =Maximum score=13 Minimum score=03	Score= 09		

The interpretation of the total Naranjo Score predicting drugaction is as follows: Define: > or = 9; Probable: 5-8; Possible: 1-4; and Doubtful: < or = 0

Discussion

This case report followed HOME-CASE guidelines for reporting the outcomes. This case was a confirmed case ofsecondary infertility with uterine fibroid. UF affect a woman's quality of life, as well as her fertility and obstetrical outcomes. This study supports the fact that fibroids influence infertility by evaluating spontaneous conception in infertile women with and without fibroid inwhich found a significant discrepancy in pregnancy rate forinfertile women (11% with fibroids versus 25% without fibroids) and removing the fibroids increased the pregnancyrate from 25% to 42% [26]. The fifteen included studies thatdisplayed a lower Implantation Rate in women with noncavity-distorting intramural fibroids than in womenwithout fibroid [7] The indications of surgery in a womanwho is considering the possibility of pregnancy by thenatural methods with the presence of submucous or intramural fibroid, greater 3 cm in size [27]. Here, with theindividualized constitutional homoeopathic treatment, the larger intramural fibroid (>3cm) regressed significantly as well as implanted successfully and conceive spontaneously. Although the most pregnancies with fibroids are uneventfulbut the risk of developing complications occur in approximately 10-40% of pregnancies (23, 24) andincreases the risk if the fibroids are over 3 cm in size. [27] Inthis case there was no developing any complicationsthroughout the pregnancy and patient delivered normally afull term healthy female child at local Government Hospital without any complications.

Kalampokas *et al* [28] presented a case series in the literature in which homoeopathic treatment showed successful result on female infertility patient. It has been shown in case study Oberai *et al* [29] which showed effective role of homoeopathy in management of fibroids as well as in case reports , Parveen *et al* [30] and Rath *et al* [31] that homoeopathy have shown the effective role in cases of infertility. This case clearly revealed the effectiveness of individualized constitutional homoeopathy medicine in treatment of infertility and UF.

Conclusion

This case report has shown the constitutional individualized homoeopathic medicines can also improve the fertility of patients with history of infertility and uterine fibroid with no additional obstetric complications. Homoeopathy can be a good alternative treatment for management of uterine fibroid and infertility. However, well designed studies are required for establishing the effectiveness and efficacy of Homoeopathy in treating infertility cases.

References

1. 1. Purohit P, Vigneswaran K. Fibroids and Infertility. Curr Obstet Gynecol Rep 2016; 5:81-88. DOI: 10.1007/s13669-016-0162-2.

   2. Elugwaraonu O, Okojie AIO, Okhia O, and Oyadoghan GP. The prevalence of uterine fibroids in women of reproductive age. IJBAIR. 2013; 2(3): 55-60.

   3. ASRM Practice Committee. Reproductive function and myomas.Fertil Steril. 2006; 86:S194-9. This article analyzes the current methods of managing fibroid and also investigates the correlation between the fibroid and reproductive function.

   4. Bulun SE. "Uterine fibroids." The New England Journal of Medicine, 2013; 369(14):1344-1355.

   5. Buttram Jr VC, Reiter RC. "Uterine leiomyomata: etiology, symptomatology, and management." Fertility and Sterility, 1981; 36(4):433-445.

   6. Verkauf BS. "Myomectomy for fertility enhancement and preservation." Fertility and Sterility. 1992; 58(1): 1-15.

   7. Wang Li Chen X, Hengyu Wang, Qin Li, Xiru Liu, and Hongbo Qi. The Efficacy of In Vitro Fertilization-Embryo Transfer: An Updated Meta-Analysis of Noncavity-Distorting Intramural Fibroids; September, 2018.

   8. Pritts EA, Parker WH, Olive DL. "Fibroids and infertility: an updated systematic review of the evidence." Fertility and Sterility. 2009; 91(4):1215-1223.

   9. Eldar-Geva T, Meagher S, Healy DL, MacLachlan V, Breheny S, Wood C. "Effect of intramural, subserosal, and submucosal uterine fibroids on the outcome of assisted reproductive technology treatment." Fertility and Sterility. 1998; 70(4):687-691.

   10. Donnez J, Jadoul P. What are the implications of myomas on fertility? The necessity of a debate? Hum Reprod. 2002; 17:1424-30.

   11. Dubuisson JB, Fauconnier A, Chapron C, Kreiker G, Nörgaard C. The subsequent examination following a laparoscopic myomectomy. Hum Reprod. 1998; 13(8): 2102-6.

   12. Guo XC, BS, and James H. Segars; The Impact

and Management of Fibroids for Fertility: an Evidence-Based Approach; Obstetrics and Gynecology Clinics of North America, 2012.

13. Iqbal JQ, Ali S, Vatsalya B, Ponnan HB, Nikhat PS. The role of homoeopathic medications in the treatment of uterine

A prospective observational study of fibroid. Indian Journal of Research in Homoeopathy. 2012; 6: 3–14.

14. Popov AV. The use of homoeopathy in the treatment of uterine fibromyoma. Br Homeopath J 1992; 81:164-7.

15. Iqbal JQ, Ali S, Nikhat PS, Vatsalya B. A case of uterine fibroid. Indian Journal of Research in Homoeopathy 2008; 2: 50–8. Indian Journal of Research in Homoeopathy 2008; 2: 50–8.

16. Singh Rahul. A case study A Study of the Efficacy of Homoeopathic Medicines in the Treatment of Infertility Caused by Uterine Fibroids Without the Need for Surgical Intervention; ACTA Scientific Medical Sciences. 2019; 3(2):56-62

17. Masiello DJ, loike JD. A Medical and Biothetic Perspective on Homoeopathic Treatment of Infertility. In the International Journal of Complementary and Alternative Medicine, 2017; 5:0016.

18. Organon of Medicine. 6th ed. New Delhi: B. Jain Publishers (P) Ltd, 2011. Hahnemann S.

19. Shah J. Hompath Ver. 1.0 of the Classic M.D. Repertory. Mind Technologies Pvt. Ltd., Mumbai, India; 2002

20. Kent J. T. Repertory of the Homoeopathic Materia Medica, Reprint Edition. 1999, New Delhi, B. Jain Publishers Pvt. Ltd.

21. Ramanlal PP. Chronic Miasms in Homoeopathy and their Cure with Classification of their Rubrics/Symptoms in Dr. Kent's Repertory (Repertory of Miasms); Indian Edition; New Delhi IBPP, 1996.

22. Allen JH. The Chronic Miasms Psora and Pseudo-Psora. Rep ed., Vol. I & II. New Delhi: B. Jain Publishers (P) Ltd. 2006, 51-277.

23. Boericke W. New Manual of Homoeopathic Materia Medica & Repertory. New Delhi: B. Jain Publishers (P) Ltd, 2001; 507-11, 655-59.

24. Allen HC. Keynotes and Characteristics with Comparisons of Some of the Leading Remedies of the Materia Medica with Bowel Nosodes. Rep. ed. New Delhi: B. Jain Publishers (P) Ltd.; 1998, 219-22, 296-98.

25. Van Haselen RA. Development of a supplement (HOM-CASE) to the CARE clinical case reporting guideline: Homeopathic clinical case reports. Complement Ther Med 2016; 25:78-85.

26. Buletti C, De Ziegler D, Polli V, Flamigni C. The significance of leiomyomas in infertility. J Am Assoc Gynecol Laparosc. 1999; 6:441-5.

27. Porozhanova V, Porozhanova K. Uterine fibromas and infertility; Akush Ginekol (Sofiia). 2004; 43(6):33-8.

28. Kalampokas T, Botis S, Antoniou Kedikgianni, Papamethodiou D, Kivellos S, Papadimitriou V et al. A case series on homoeopathy for the treatment of infertility.Clin. Exp. Obst. & Gyn. 2014; XLI(6):158-159.

29. Oberoi, P., Indira, B., Varanasi, R., et al. A multricentric randomized clinical trial of homoeopathic remedies in fifty millesemal potencies vis-à-vis centesimal potencies on symptomatic uterine fibroids; Indian Journal of Research in Homoeopathy; 2016; 10:24-35

30. Parveen S, Bhowmick H. The Impact of Individualized Homoeopathy on the Treatment of Infertility. Indian Journal of Research in Homoeopathy; 2018; 12:231-39.

31. Rath P Goswami. A; A case of infertility with PCOD treated with noninvasive homoeopathy. Journal of Advancements in Homoeopathic Research, 2018.